



and Other Interventional Techniques

## Comparison of intraabdominal pressures using the gastroscope and laparoscope for transgastric surgery

O. Meireles,<sup>1</sup> S. V. Kantsevoy,<sup>2</sup> A. N. Kalloo,<sup>2</sup> S. B. Jagannath,<sup>2</sup> S. A. Giday,<sup>2</sup> P. Magno,<sup>2</sup> S. P. Shih,<sup>1</sup> E. J. Hanly,<sup>1</sup> C.-W. Ko,<sup>2</sup> D. M. Beitler,<sup>2</sup> M. R. Marohn<sup>1</sup>

<sup>1</sup> Department of Surgery, Johns Hopkins University School of Medicine, 600 N. Wolfe Street, Halsted 608, Baltimore, MD, 21287, USA

<sup>2</sup> Division of Gastroenterology, Johns Hopkins University School of Medicine, 600 N. Wolfe Street, Halsted 608, Baltimore, MD, 21287, USA

Received: 2 October 2006/Accepted: 16 October 2006/Online publication: 3 April 2007

### Abstract

**Background:** The peroral transgastric endoscopic approach for intraabdominal procedures appears to be feasible, although multiple aspects of this approach remain unclear. This study aimed to measure intraperitoneal pressure in a porcine model during the peroral transgastric endoscopic approach, comparing an endoscopic on-demand insufflator/light source with a standard autoregulated laparoscopic insufflator.

**Methods:** All experiments were performed with 50-kg female pigs under general anesthesia. A standard upper endoscope was advanced perorally through a gastric wall incision into the peritoneal cavity. The peritoneal cavity was insufflated with operating room air from an endoscopic light source/insufflator. Intraperitoneal pressure was measured by three routes: (1) through the endoscope biopsy channel, (2) through a 5-mm transabdominal laparoscopic port, and (3) through a 16-gauge Veress needle inserted into the peritoneal cavity through the anterior abdominal wall. The source of insufflation alternated between on-demand manual insufflation through the endoscopic light source/insufflator using room air and a standard autoregulated laparoscopic insufflator using carbon dioxide (CO<sub>2</sub>).

**Results:** Six acute experiments were performed. Intraperitoneal pressure measurements showed good correlation regardless of measurement route and were independent of the type of insufflation gas, whether room air or CO<sub>2</sub>. On-demand insufflation with the endoscopic light source/insufflator resulted in a wide variation in pressures (range, 4–32 mmHg; mean, 16.0 ± 11.7). Intraabdominal pressures using a standard autoregulated laparoscopic insufflator demonstrated minimal fluctuation (range, 8–15 mmHg; mean, 11.0 ± 2.2 mmHg) around a predetermined value.

**Conclusion:** Use of an on-demand unregulated endoscopic light source/insufflator for transluminal surgery can cause large variation in intraperitoneal pressures and intraabdominal hypertension, leading to the risk of hemodynamic and respiratory compromise. Safety may favor well-controlled intraabdominal pressures achieved with a standard autoregulated laparoscopic insufflator.

**Key words:** Autoregulated laparoscopic insufflator — Endoscopic on-demand insufflator/light source — Intraabdominal pressure — Intraperitoneal pressure — Peroral transgastric endoscopic approach — PTE — NOTES

Several investigators have demonstrated the feasibility of using transgastric peritoneoscopy to carry out diagnostic and therapeutic interventions for intraabdominal organs [2, 7, 9–11, 15, 17, 18]. Similar to laparoscopic procedures, transgastric surgery requires a pneumoperitoneum to create a potential working space. Laparoscopic insufflators are autoregulated and generate stable preset intraabdominal pressure using carbon dioxide (CO<sub>2</sub>) gas.

Our previous transgastric experiments have demonstrated that adequate pneumoperitoneum can be created through hand-activated on-demand insufflation with operating room air using a standard flexible endoscope and a standard endoscopic light source/insufflator [9]. Standard endoscopic light source/insufflators do not, however, monitor or regulate intraperitoneal pressure from the insufflated room air.

The current study aimed to measure intraperitoneal pressure in a live porcine model during transgastric surgery, comparing insufflation from an endoscopic unregulated light source/insufflator using room air with a standard autoregulated laparoscopic insufflator using CO<sub>2</sub>.

Presented in part at the Society of American Gastrointestinal and Endoscopic Surgeons (SAGES) Annual Meeting, April 2006, Dallas, TX, USA

Correspondence to: M. R. Marohn

## Methods

This study was approved by the Johns Hopkins University School of Medicine Animal Care Institutional Review Board. We performed six acute experiments using 50-kg pigs (*Sus scrofa domestica*). All procedures were performed with the animals under 1.5% to 2% isoflurane general anesthesia using 7-mm endotracheal intubation (Mallinckrodt Co, C. D. Juarez, Chih, Mexico). Preanesthesia medications consisted of intramuscular injection of 100 mg/ml Telazol (tiletamine HCl C zolazepam HCl; Lederle Parenterals, Inc, Carolina, Puerto Rico) reconstituted with 100 mg/ml of ketamine HCl and 100 mg/ml of xylazine at a total dose of approximately 0.05 ml/kg. The marginal ear vein was injected with 1 g of thiopental sodium at a dose of 6.6 to 8.8 mg/kg.

A forward-viewing double-channel upper endoscope (GIF-2T160; Olympus Optical Co Ltd., Tokyo, Japan) inside an overtube (Olympus Optical Co Ltd.) was advanced into the pig's stomach. A 20-mm-long gastrotomy was completed with an endoscopic needle knife (KD-10Q-1.A; Olympus Optical Co Ltd.) and a pull-type sphincterotome (210Q-0720; Olympus Optical Co Ltd.), as previously described [9, 10, 11].

The endoscope was advanced into the peritoneal cavity, and pneumoperitoneum was created using hand-activated on-demand insufflation of operating room air through the endoscope from a standard endoscopic light source/insufflator. To assess the intraperitoneal pressure, a 16-gauge Veress needle was placed into the peritoneal cavity through puncture of the anterior abdominal wall in the left upper quadrant and connected via a stopcock and tubing system to a standard autoregulated laparoscopic insufflator equipped with a built-in manometer (Electronic Endoflator 264305 20; Karl Storz, Tuttlingen, Germany) that had the insufflation mode turned off.

Next, the laparoscopic insufflator tubing was disconnected from the Veress needle and switched to another stopcock connected to a 5-mm laparoscopic trocar placed through the abdominal wall in the mid-abdomen to validate pressure measurement correlation. The tubing finally was connected to the flexible endoscope biopsy channel via a stopcock to correlate pressure measurement as well.

All procedures started with hand-activated on-demand insufflation, then switched to automated mode, with a setting point pressure of 12 mmHg and 10 l/min of CO<sub>2</sub>. Transgastric cholecystectomy was performed using a flexible endoscope under laparoscopic observation according to a previously described technique. The cystic artery and duct were clipped with single-use endoscopic clips (Resolution; Boston Scientific Microvasive, Natick, MA, USA) or a multiple clip applicator (Ethicon, Endo-Surgery Inc, Cincinnati, OH, USA). The cystic artery and duct were divided, and the gallbladder was separated from the liver with the needle knife (KD-10Q-1.A; Olympus Optical Co Ltd.). The specimen was removed from the peritoneal cavity through the gastric wall incision.

The insufflation source was changed every 10 min, alternating between on-demand insufflation from a standard unregulated endoscopic light source/insufflator using operating room air and a standard autoregulated laparoscopic insufflator using CO<sub>2</sub> gas. During each procedure, a preassigned member of the research team gathered the pressure data from three different sites every 10 min: from a 16-gauge Veress needle placed across the abdominal wall, from the biopsy channel of the flexible endoscope, and from a 5-mm laparoscopic trocar inserted into the peritoneal cavity through the anterior abdominal wall. Three-way stopcocks were placed at each site to facilitate pressure measurements from each site without loss of insufflated gas. The pressure was measured by connecting the laparoscopic insufflator tubing to the site to be measured, and the numbers were recorded on a dedicated sheet per procedure.

The pressure from the three sites for each interval were recorded, and the mean pressure was placed in a table for statistical correlation using one-way analysis of variance (ANOVA). Also, the mean pressure from the three sites of measurement during hand-activated and automated insufflations were used to compare statistical differences between the pressures generated with the two different methods of insufflation using the *t*-test.

After the pressure numbers were obtained and before the insufflation mode was switched, the pneumoperitoneum was deflated to a pressure of 5 mmHg to avoid overlapping of the working space from the previous mode with the next. Then the necessary insufflation to create a new working space was provided.

**Table 1.** Comparison of intraabdominal pressure measurements (mmHg) during insufflation

	Hand activated on-demand insufflation (minutes)					Automated laparoscopic insufflation (minutes)				
	10	30	50	70	Mean	20	40	60	80	Mean
1	4	18	32 <sup>a</sup>	18	18	15	8	13	11	12
2	12	6	18	24	15	12	13	10	11	11.5
3	8	22	8	6	11	12	13	9	10	11
4	18	10	8	24	15	11	10	10	11	10.5
5	28 <sup>a</sup>	18	12	18	19	9	10	11	10	10
6	16	8	20	28 <sup>a</sup>	18	10	12	11	11	11
Range	4–32					8–15				
Mean	16.0					11.0				
SEM	1.21					0.29				

<sup>a</sup> Untoward hemodynamic and/or respiratory events noted

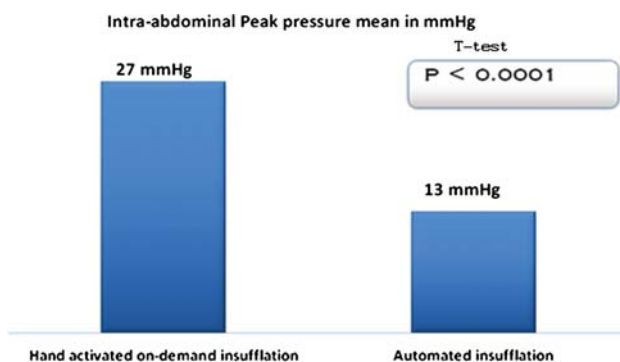
Each animal had pulse oxymetry to assess oxygenation and pulse. No invasive monitoring was used to assess hemodynamic changes. After completion of the endoscopic cholecystectomy, the animals were sacrificed, and necropsy was performed.

## Results

All cholecystectomies were performed using a flexible endoscope and endoscopic accessories. During insufflation using the standard autoregulated laparoscopic insufflator, we selected a set point of 12 mmHg, based on common clinical safety experience and published animal data on safe intraabdominal pressure for surgical pneumoperitoneum [1, 3, 8, 14]. Intraabdominal pressure measurements showed good correlation without statistically significant differences between the three measurement routes (a Veress needle, the biopsy channel of the endoscope, or a standard laparoscopic trocar) according to one-way analysis of variance (ANOVA) using a *p* value of 0.97.

Table 1 presents the interval intraabdominal pressure measurements under both insufflation conditions: on-demand unregulated endoscopic light source/insufflator and autoregulated laparoscopic insufflator. Hand-activated on-demand insufflation through the gastroscop using a standard endoscopic light source/insufflator showed a wide variation in intraabdominal pressures (range, 4–32 mmHg; mean, 16.0 ± 11.7 mmHg). In contrast, when the standard autoregulated laparoscopic insufflator with CO<sub>2</sub> gas was used, there were minimal fluctuations around the predetermined set value of 12 mmHg (range, 8–15 mmHg; mean, 11.0 ± 2.2 mmHg). The difference between the mean pressures from the two groups was statistically significant (*p* = 0.00054, *t*-test). The peak pressure was significantly higher when the on-demand endoscopic insufflator was used, showing statistical significance with the *t*-test (*p* < 0.0001) (Fig. 1).

During insufflation with the autoregulated laparoscopic insufflator using CO<sub>2</sub> gas, there were no signs of hemodynamic instability or ventilatory problems. Despite the wide fluctuations in intraabdominal pressure during unregulated hand-activated insufflation of room



**Fig 1.** Comparison of peak intraabdominal pressures during insufflation.

air through the flexible endoscope from the endoscopic light source/insufflator, only rare signs of tachycardia and difficulty with ventilation were noted by the veterinarian staff. This correlated with intraabdominal hypertension exceeding 25 mmHg during hand insufflations.

Necropsy did not show any signs of bleeding, intestinal or liver injury, or other procedure-related complications.

## Discussion

Laparoscopic procedures are now widely used and recognized as safe, less invasive alternatives to traditional “open” surgery [4, 12, 13]. Transgastric endoscopic procedures hold the prospect of eliminating any incision in the abdominal wall and of potentially further reducing the invasiveness of currently available surgical procedures [16].

Multiple studies have demonstrated the feasibility of the transgastric endoscopic approach for diagnostic and therapeutic interventions within the peritoneal cavity [2, 7, 9–11, 15, 17, 18]. Many questions remain, however, regarding peroral transgastric interventions. The aim of these acute experiments was to measure and compare intraperitoneal pressure in transgastric endoscopic cholecystectomy using the gastroscope during hand-activated on-demand insufflation of operating room air from a hand-controlled endoscopic light source/insufflator with insufflation using CO<sub>2</sub> gas from a standard autoregulated laparoscopic insufflator.

Our experiments demonstrated good correlation of intraabdominal pressure measurements obtained through any of three different routes: through a 16-gauge Veress needle placed across the abdominal wall, through the biopsy channel of the flexible endoscope, and through a 5-mm laparoscopic trocar inserted into the peritoneal cavity through the anterior abdominal wall.

During insufflation using a standard autoregulated laparoscopic insufflator, intraabdominal pressures varied little around a preselected set point of 12 mmHg. We selected 12 mmHg as our set point on the basis of conventional laparoscopic experience that has established 15 mmHg as the upper limit for safe intraabdominal pressure, with intraabdominal hypertension and associated untoward effects expected above 20 to 25 mmHg [1, 3, 8, 14]. In our experiments, the intraabdominal

pressures demonstrated minimal variation (range, 8–15 mmHg; mean, 11.1 ± 2.2 mmHg). Automated insufflation of CO<sub>2</sub> via the laparoscopic insufflator significantly decreased variations in intraabdominal pressure. Use of the standard autoregulated laparoscopic insufflator for transgastric surgery maintained intraabdominal pressure within what is recognized as safe levels, with the highest peak pressure reaching 15 mmHg.

During the periods of hand-activated on-demand insufflation through the gastroscope from a standard hand-activated endoscopic light source/insufflator, wide variation in intraabdominal pressure was observed (range, 4–32 mmHg; mean, 16 ± 11.7 mmHg).

Hand-activated insufflation generated intraabdominal pressures as high as 32 mmHg, more than twice the traditional 15 mmHg level recognized in laparoscopic surgery as the upper limit for safe pneumoperitoneum. These large variations and episodes of high intraabdominal hypertension potentially can lead to hemodynamic and/or respiratory adverse effects. Even in our relatively small series of six animals, we noted occasional hemodynamic instability, ventilatory difficulties, or both during periods of hand-activated insufflation, which correlated with intraabdominal pressures greater than 25 mmHg.

Intraabdominal pressure measurements did not vary according to the insufflated gas used, whether room air or CO<sub>2</sub>. The pneumoperitoneum was adequate regardless of the source of insufflation or gas used for insufflation.

Room air is routinely used for endoscopic procedures inside the gastrointestinal tract. It has the advantage of universal availability without extra cost. It was not a purpose of our study to compare the differences between CO<sub>2</sub> and room air because these have been exhaustively studied and reported in the laparoscopic literature [17]. However, it is still important to stress that room air carries the risk of combustion if used for procedures in which cauterization or laser use are required. Also, room air has been associated with a greater rate of wound infection than CO<sub>2</sub> [6], which in addition has been shown to modulate the peritoneal host defenses and inflammatory response to sepsis [5]. Therefore, during transgastric intraperitoneal procedures, CO<sub>2</sub> insufflation will have multiple advantages over the room air insufflation via the flexible endoscope.

In conclusion, the use of the on-demand unregulated endoscopic light source/insufflator for transluminal surgery can cause large variation in intraperitoneal pressures and intraabdominal hypertension, leading to hemodynamic and respiratory compromise. Safety may favor well-controlled intraabdominal pressures achieved with a standard autoregulated laparoscopic insufflator.

## References

1. Barnes GE, Laine GA, Giam PY, Smith EE, Granger HJ (1985) Cardiovascular responses to elevation of intraabdominal hydrostatic pressure. *Am J Physiol* 248: R209
2. Bergstrom M, Ikeda K, Swain P, Park PO (2006) Transgastric anastomosis by using flexible endoscopy in a porcine model (with video). *Gastrointest Endosc* 63: 307–312

3. Booker WM, French DM, Molano PA (1947) Further studies on the acute effects of intraabdominal pressure. *Am J Physiol* 149: 92–98
4. Brunt LM, Langer JC, Quasebarth MA, Whitman ED (1996) Comparative analysis of laparoscopic versus open splenectomy. *Am J Surg* 172: 596–599; discussion 599–601
5. Hanly EJ, Mendoza-Sagaon M, Murata K, Hardacre JM, DeMaio A, Talamini MA (2003) CO<sub>2</sub> pneumoperitoneum modifies the inflammatory response to sepsis. *Ann Surg* 237: 343–350
6. Ikechebelu JI, Obi RA, Udigwe GO, Joe-Ikechebelu NN (2005) Comparison of carbon dioxide and room air pneumoperitoneum for day-case diagnostic laparoscopy. *J Obstet Gynaecol* 25: 172–173
7. Jagannath SB, Kantsevov SV, Vaughn CA, Chung SS, Cotton PB, Gostout CJ, Hawes RH, Pasricha PJ, Scorpio DG, Magee CA, Pipitone LJ, Kalloo AN (2005) Peroral transgastric endoscopic ligation of fallopian tubes with long-term survival in a porcine model. *Gastrointest Endosc* 61: 449–453
8. Joris JL, Noirot DP, Legrand MJ, Jacquet NJ, Lamy ML (1993) Haemodynamic changes during laparoscopic cholecystectomy. *Anesth Analg* 76: 1067–1071
9. Kalloo AN, Singh VK, Jagannath SB, Niiyama H, Hill SL, Vaughn CA, Magee CA, Kantsevov SV (2004) Flexible transgastric peritoneoscopy: a novel approach to diagnostic and therapeutic interventions in the peritoneal cavity. *Gastrointest Endosc* 60: 114–117
10. Kantsevov SV, Hu B, Jagannath SB, Vaughn CA, Beitler DM, Chung SS, Cotton PB, Gostout CJ, Hawes RH, Pasricha PJ, Magee CA, Pipitone LJ, Talamini MA, Kalloo AN (2006) Transgastric endoscopic splenectomy: Is it possible? *Surg Endosc* 20(3): 522–5
11. Kantsevov SV, Jagannath SB, Niiyama H, Chung SS, Cotton PB, Gostout CJ, Hawes RH, Pasricha PJ, Magee CA, Barlow D, Shimonaka H, Kalloo AN (2005) Endoscopic gastrojejunostomy with survival in a porcine model. *Gastrointest Endosc* 62: 287–292
12. Morales-Conde S, Cadet H, Cano A, Bustos M, Martin J, Morales-Mendez S (2005) Laparoscopic ventral hernia repair without sutures—double crown technique: our experience after 140 cases with a mean follow-up of 40 months. *Int Surg* 90: S56–S62
13. Muckleroy SK, Rutzer ER, Fenoglio ME (1999) Laparoscopic colon surgery for benign disease: a comparison to open surgery. *JSL* 3: 33–37
14. Odeberg S, Ljungqvist O, Svenberg T, Gannedahl P, Backdahl M, Von Rosen A, Sollevi A (1994) Haemodynamic effects of pneumoperitoneum and the influence of posture during anaesthesia for laparoscopic surgery. *Acta Anaesthesiol Scand* 38: 276–283
15. Park PO, Bergstrom M, Ikeda K, Fritscher-Ravens A, Swain P (2005) Experimental studies of transgastric gallbladder surgery: cholecystectomy and cholecystogastric anastomosis (videos). *Gastrointest Endosc* 61: 601–606
16. Rattner D, Kalloo A (2006) ASGE/SAGES Working Group on Natural Orifice Translumenal Endoscopic Surgery. October 2005. *Surg Endosc* 20: 329–333
17. Wagh MS, Merrifield BF, Thompson CC (2005) Endoscopic transgastric abdominal exploration and organ resection: initial experience in a porcine model. *Clin Gastroenterol Hepatol* 3: 892–896
18. Wagh MS, Merrifield BF, Thompson CC (2006) Survival studies after endoscopic transgastric oophorectomy and tubectomy in a porcine model. *Gastrointest Endosc* 63: 473–478